□□□□□□□□□□Vol.11□□□□□□□□□□□□

□□□□□□□□□

Vol.11□□□□□□□□□□□□□□□□□□□□□□□

□□□□	50□□□
□□□□	□□□□□□□
□□□□□	□□□□□□□□□□□□□□□□□□□□□
□□□□□	□□□□□□□□□IBD□AS□□□□□□□RA□□□

□□□□□□□□□ □□□□□□□□□□□□□□□□□□□□□□ □□□ □□ □□ □□

□□□
□□□□□□□□□

□□□□
□□□□□□□□□□□□□□RA

□□□□□
□□□□□□□□□□□□□□□□□□□□□Psoriatic onycho-pachydermo periostitis:POPP□□□□□□□□□□□□□□□□□□□

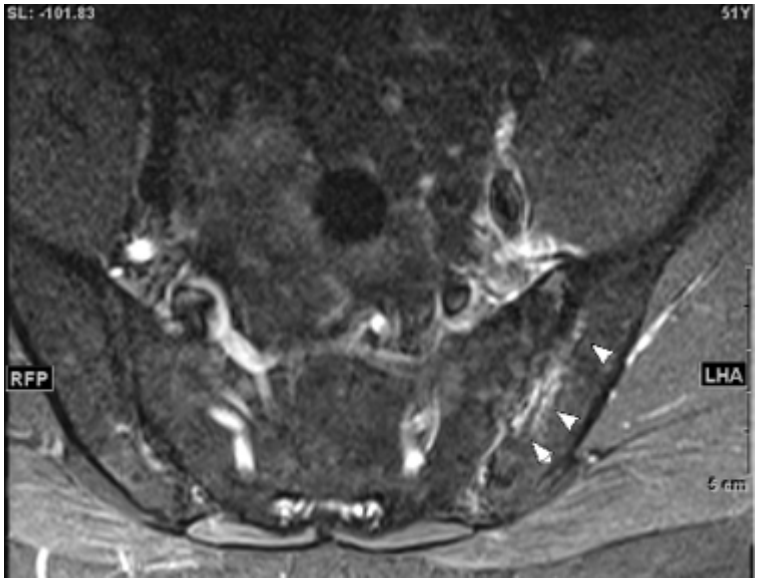

Image

Image

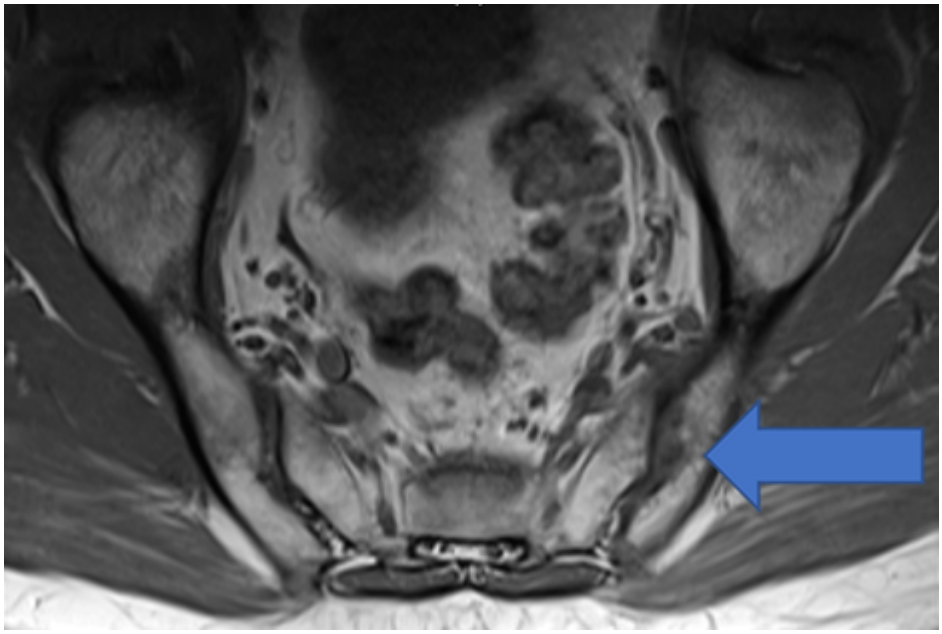

□□□□□Ann Rheum Dis. 2024 Aug 6:ard-2024-225882.

CTX00044JG0001
2024□12□

□□□□□
□□□□□□□□□□ □□□□□□□

□□□□□□□□□□□□□□□□

□□□□□□

Source URL:
https://www.pro.novartis.com/jp-ja/support/lecture/joint_finding/case011_answer_11